

What is a thyroid nodule?

The thyroid gland is located in the lower front of the neck, below the larynx (“Adam’s apple”) and above the collarbones. A thyroid nodule is a lump in or on the thyroid gland. Thyroid nodules are common and occur in about 4% of women and 1% of men; they are less common in younger patients and increase in frequency with age. Sometimes several nodules will develop in the same person. Any time a lump is discovered in thyroid tissue, the possibility of malignancy (cancer) must be considered. Fortunately, the vast majority of thyroid nodules are benign (not cancerous).

Many patients with thyroid nodules have no symptoms whatsoever, and are found by chance to have a lump in the thyroid gland on a routine physical exam or an imaging study of the neck done for unrelated reasons (CT or MRI scan of spine or chest, carotid ultrasound, etc). However, a minority of patients may become aware of a gradually enlarging lump in the front portion of the neck, and/or may experience a vague pressure sensation or discomfort when swallowing. Obviously, finding a lump in the neck should be brought to the attention of your physician, even in the absence of symptoms.

Nodules can be caused by a simple overgrowth of normal thyroid tissue, fluid-filled cysts, inflammation (thyroiditis), or a tumor (either benign or cancerous). Most nodules were surgically removed until the 1980s. In retrospect, this approach led to many unnecessary operations, since fewer than 10% of the removed nodules proved to be cancer. Most removed nodules could have simply been observed or treated medically.

It is not usually possible for a physician to determine whether a thyroid nodule is cancerous on the basis of a physical examination or blood tests. Endocrinologists rely heavily on 3 specialized tests for help in deciding which nodules should be treated surgically:

- Thyroid fine needle biopsy
- Thyroid scan
- Thyroid ultrasonography

What is a thyroid needle biopsy?

A thyroid fine needle biopsy is a simple procedure that can be performed in the physician’s office. Many physicians numb the skin over the nodule prior to the biopsy, but it is not necessary to be put to sleep, and patients can usually return to work or home afterward with no ill effects. This test provides specific information about a particular patients’ nodule, information that no other test can offer short of surgery. Although the test is not perfect, a thyroid needle biopsy will provide sufficient information on which to base a treatment decision more than 75% of the time, eliminating the need for additional diagnostic studies. Use of fine needle biopsy has drastically reduced the number of patients who have undergone unnecessary operations for benign nodules. However, about 15 - 20% of biopsy specimens are interpreted as inconclusive or inadequate, that is, the pathologist cannot be certain whether the nodule is cancerous or benign. This situation is particularly common with cystic (fluid-filled) nodules, which contain very few thyroid cells to examine, and with those nodules composed of a particular cell type called follicular. In such cases, a physician who is experienced with thyroid disease can use other criteria to make a decision about whether or not to operate. The fine needle biopsy can be repeated in those patients whose initial attempt failed to yield enough material to make a diagnosis, using thyroid ultrasonography to guide the needle placement if necessary.

What is a thyroid scan?

A thyroid scan is a picture of the thyroid gland taken after a small dose of a radioactive isotope normally concentrated by thyroid cells has been injected or swallowed. The scan tells whether the nodule is hyperfunctioning (a “hot” nodule), functioning along

with the rest of the thyroid gland (a “warm” nodule), or not functioning (a “cold” nodule). Because cancer is rarely found in hot nodules, a scan showing a hot nodule eliminates the need for fine needle biopsy. If a hot nodule causes hyperthyroidism, it can be treated with radioiodine or surgery.

Fortunately, the vast majority (90 - 95%) of thyroid nodules are benign. Unfortunately, thyroid scans show that most thyroid nodules, both benign and malignant, are cold or non-functioning. Therefore, although almost all thyroid cancers are nonfunctional on scan, the majority of nonfunctional nodules are benign.

For this reason, thyroid scans are of relatively little value in most patients unless hyperthyroidism exists along with the nodule.

What is thyroid ultrasonography?

Thyroid ultrasonography is a procedure for obtaining pictures of the thyroid gland by using high-frequency sound waves that pass through the skin, bounce off the inner structures of the neck, and are converted into a “live” image by a computer. It can visualize nodules as small as 2 to 3 mm. Ultrasound studies were first used to distinguish thyroid cysts (fluid filled nodules) from solid nodules. Cysts are usually benign, and solid nodules are potentially cancerous. Most nodules, however, have both solid and cystic components, and very few purely cystic nodules occur. Therefore, ultrasonography alone is rarely able to distinguish between a benign (noncancerous) nodule and a malignant (cancerous) one.


A more important use of thyroid ultrasonography is in guiding the placement of a biopsy needle to decrease the frequency of inadequate specimens. Such guidance allows the biopsy sample to be obtained from the solid portion of those nodules that are both solid and cystic, and it avoids getting a specimen from the surrounding normal thyroid tissue if the nodule is small.

Even when a thyroid biopsy sample is reported as benign, the size of the nodule should be monitored. A thyroid ultrasound examination provides an objective and precise method for detection of a change in the size of the nodule. A nodule with a benign biopsy that is stable or decreasing in size is unlikely to be malignant or require surgical treatment.

How are thyroid nodules treated?

Your endocrinologist will use the above mentioned tests to arrive at a recommendation for optimal management of your nodule. Most patients who appear to have benign nodules require no specific treatment, and can simply be followed expectantly. Some physicians prescribe levothyroxine with hopes of preventing nodule growth or reducing the size of cold nodules, while radioiodine maybe used to treat hot nodules.

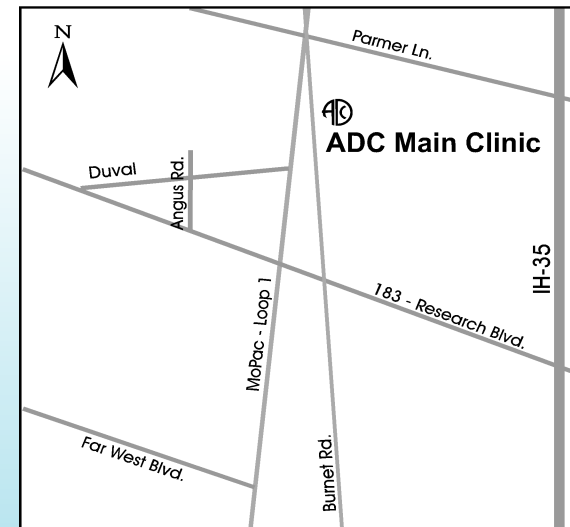
If cancer is suspected, surgical treatment will be recommended. The primary goal of therapy is to remove all thyroid nodules that are cancerous (and, if malignancy is confirmed, remove the rest of the thyroid gland along with any abnormal lymph glands). If surgery is not recommended, it is important to have regular follow-up of the nodule by a physician experienced in such an evaluation.



Thyroid Nodule



Thyroid Nodule



**The Austin Diagnostic Clinic
Endocrinology Department**
12221 MoPac Expressway North
2nd Floor, South Entrance
Austin, TX 78758-2483

Appointments:
512/901-4005

What is an Endocrinologist?

Endocrinologists specialize in gland disorders which include thyroid, diabetes, osteoporosis, menopause, impotence, and other hormone and metabolic problems.

AMERICAN ASSOCIATION OF
CLINICAL ENDOCRINOLOGISTS

Prepared by the American Association of Clinical Endocrinologists (AACE), a not-for-profit national organization of highly qualified specialists in hormonal and metabolic disorders whose primary professional activities focus on providing high-quality specialty care to patients with endocrine problems such as thyroid disease. © 2004 AACE - Permission is granted for reproduction of this publication.